MASSACHUSETTS GENERAL HOSPITAL
ENDOCRINE UNIT

Center for Skeletal Research

June 27, 2018

Calcium and phosphate homeostasis

Henry Kronenberg, MD

	Calcium ions	Phosphate ions
Extracellular		
Intracellular		

	Calcium ions	Phosphate ions
Extracellular		
Intracellular		
Concentration	10^{-7} M	1-2 x 10^{-3} M
Functions	signal for • neuronal activation • hormone secretion • muscle contraction	• structural: DNA, RNA • high energy bonds • signaling by phospho-proteins/lipids

	Calcium ions	Phosphate ions
Extracellular		
Concentration		
total, in serum	2.5×10^{-3} M	1.00×10^{-3} M
free	1.2×10^{-3} M	0.85×10^{-3} M
Functions	bone mineral blood coagulation cell adhesion (cadherin) source for intracellular	bone mineral source for intracellular
Intracellular		
Concentration	10^{-7} M	$1\text{-}2 \times 10^{-3}$ M
Functions	signal for • neuronal activation • hormone secretion • muscle contraction	• structural: DNA, RNA • high energy bonds • signaling by phospho-proteins/lipids

Regulators of mineral metabolism

- Parathyroid hormone
- Vitamin D
- Fibroblast growth factor (FGF) 23
- Calcium
- Phosphate

Regulators of mineral metabolism

- Parathyroid hormone
- Vitamin D
- Fibroblast growth factor (FGF) 23
- Calcium
- Phosphate

ON A NEW GLAND IN MAN AND SEVERAL MAMMALS[1]

IVAR SANDSTRÖM

[1] A translation from the Swedish by Dr. Carl M. Seipel of Stockholm. From *Upsala Läkareförenings Förhandlingar*, 1879-80, 15, 441-471.

roid gland even in man. Although the probability of finding something hitherto unrecognized seemed so small that it was exclusively with the purpose of completing the investigations rather than with the hope of finding something new that I began a careful examination of this region. So much the greater was my astonishment therefore when in the first individual examined I found on both sides at the inferior border of the thyroid gland an organ of the size of a small pea, which, judging from its exterior, did not appear to be a lymph gland, nor an accessory thyroid gland, and upon histological examination showed a rather peculiar structure. After several examinations not only was I convinced of the constancy of its appearance but I was also able to show that two such glands in most cases occur on each side. Since then my interest has been so predominantly centered on a deeper study of the structure and importance of these glands in man, that examinations of animals have been limited to dog, cat, rabbit, ox, and horse, and even there they have been rather scanty. However, I hope to complete a compara-

THE EXTRACTION OF A PARATHYROID HORMONE WHICH WILL PREVENT OR CONTROL PARATHYROID TETANY AND WHICH REGULATES THE LEVEL OF BLOOD CALCIUM.*

BY J. B. COLLIP.

(*From the Department of Biochemistry, University of Alberta, Edmonton, Alberta, Canada.*)

(Received for publication, December 3, 1924.)



FIG. 1. Dog 32. 59 days after thyroparathyroidectomy. In a state of tetany.

Level of calcium in blood was low.

FIG. 2. Dog 32. 59 days after thyroparathyroidectomy. Complete recovery 3 hours after subcutaneous injection of 3 cc. of parathyroid extract.

Level of calcium normalized.

Parathyroid hormone (PTH)

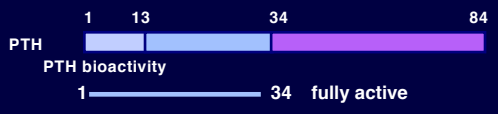

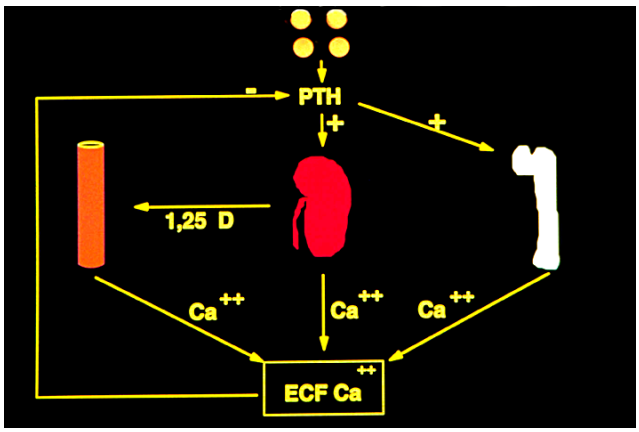

Calcium regulates PTH secretion

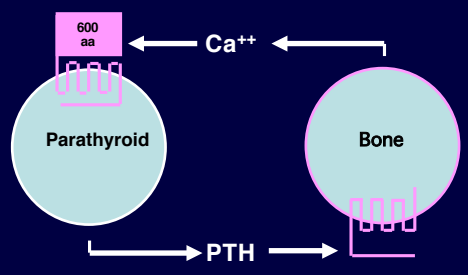

Parathyroid adenomas:one cell goes bad



Primary hyperparathyroidism:
- Too many cells
- Cells respond less well to hypercalcemia

Patient 1

The patient was in the merchant marine in WWI. Just after the war, at age 30, he noticed back pain and the beginning of loss of height. Over the next several years, he passed "gravel" in his urine.

Patient 1

The patient was in the merchant marine in WWI. Just after the war, at age 30, he noticed back pain and the beginning of loss of height. Over the next several years, he passed "gravel" in his urine.

At age 33, he fractured his upper arm and later his lower arm. X-rays showed multiple fractures and osteopenia. The diagnosis of hyperparathyroidism was suggested, and he was found to have a high level of calcium in the blood and urine. Surgery was performed and two normal parathyroid glands removed.

Patient 1

The patient was in the merchant marine in WWI. Just after the war, at age 30, he noticed back pain and the beginning of loss of height. Over the next several years, he passed "gravel" in his urine.

At age 33, he fractured his upper arm and later his lower arm. X-rays showed multiple fractures and osteopenia. The diagnosis of hyperparathyroidism was suggested, and he was found to have a high level of calcium in the blood and urine. Surgery was performed and two normal parathyroid glands removed.

At age 39, after more vertebral crush fractures and kidney stones, he underwent 4 more operations (the last 3 at MGH). At the last one, a parathyroid tumor was removed from his mediastinum. He died a few days later of sepsis in association with a renal stone.

Patient 2

This patient is an 72 year old woman who had some routine blood tests performed at the time of her annual exam.

Laboratory tests revealed:
Calcium 10.9 mg/dl (normal 8.5-10.3)
Phosphorus 2.3 mg/dl (normal 2.5-4.5)
25-OH vitamin D 28 ng/ml (normal 25-40)
Parathyroid hormone 80 ng/ml (normal 15-65)

Why is the blood level of calcium elevated?

Calcium Homeostasis: PTH action

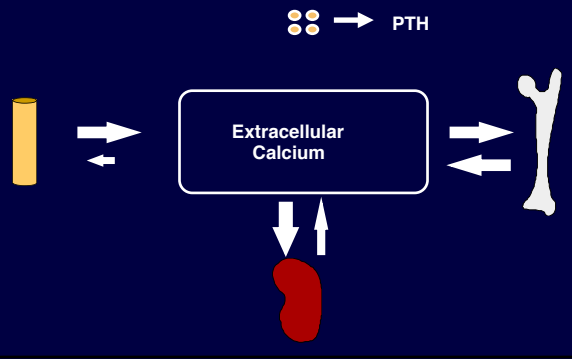

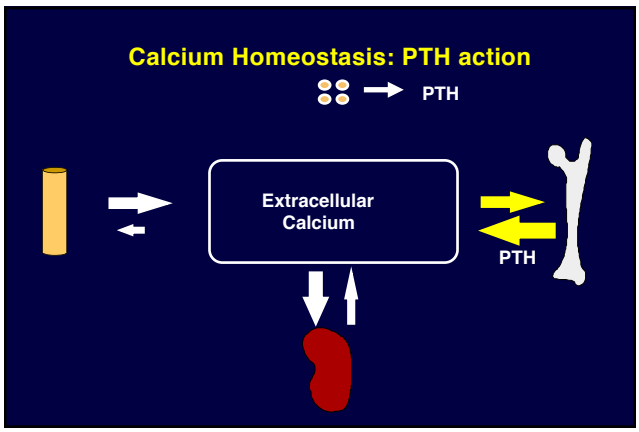
Calcium Homeostasis: PTH action
PTH
Extracellular Calcium
PTH

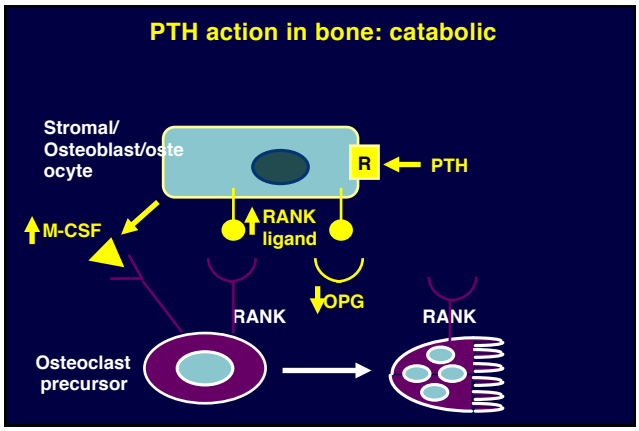
PTH action in bone: catabolic
Stromal/ Osteoblast/oste ocyte
R
PTH
M-CSF
RANK ligand
OPG
RANK
RANK
Osteoclast precursor

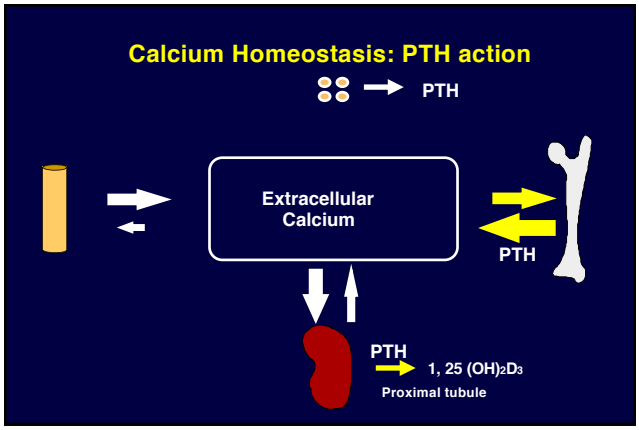
Calcium Homeostasis: PTH action
PTH
Extracellular Calcium
PTH
PTH
1, 25 (OH)2D3
Proximal tubule

Calcium Homeostasis: PTH action

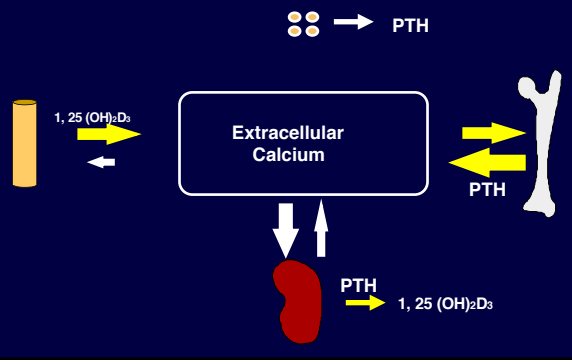

Calcium Homeostasis: PTH action

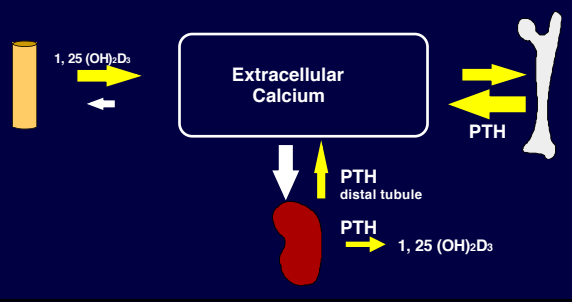

Patient 2

This patient is an 72 year old woman who had some routine blood tests performed at the time of her annual exam.

Laboratory tests revealed:
Calcium 10.9 mg/dl (normal 8.5-10.3)
Phosphorus 2.3 mg/dl (normal 2.5-4.5)
25-OH vitamin D 28 ng/ml (normal 25-40)
Parathyroid hormone 80 ng/ml (normal 15-65)

Why is the blood level of phosphorus low?

Phosphate Metabolism

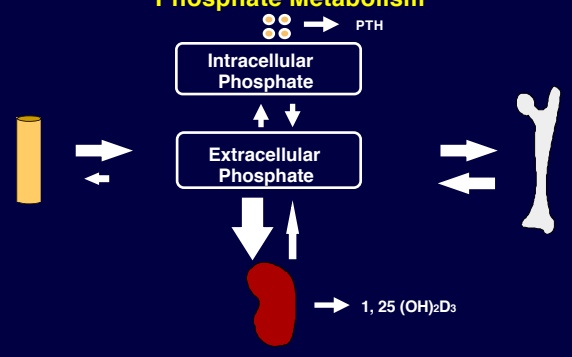

Phosphate Metabolism: roles of PTH

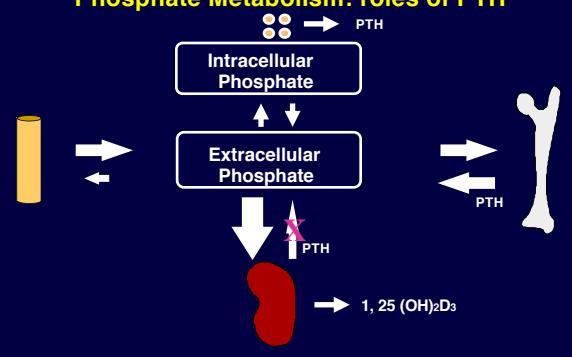

Phosphate Metabolism: roles of PTH

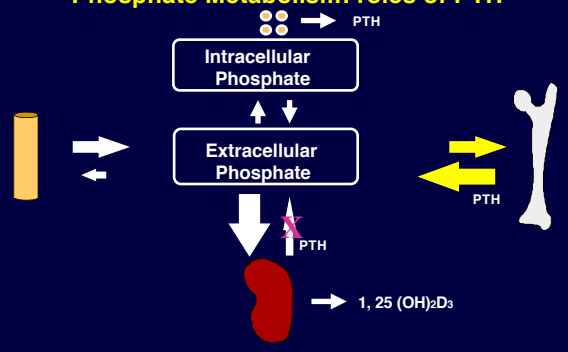

Regulators of mineral metabolism

- Parathyroid hormone
- Vitamin D
- Fibroblast growth factor (FGF) 23
- Calcium
- Phosphate

Rickets/osteomalacia: vitamin D deficiency

- First characterized in northern Europe in the 17th century
- Progressively worse with industrialization
- Two approaches seemed to help:
  - Sunlight exposure of skin
  - Cod liver oil by mouth

Classic experiment: Kinderklinik in Vienna, early 1920's



Four groups:

Inside:
- Diet with cod liver oil
- Diet without cod liver oil

Outside:
- Exposure to sunlight
- Subjects kept in shade

Cod liver oil: bubble oxygen through, destroyed vitamin A but not the new vitamin D, the cure for rickets

Vitamin D increased calcium absorption through intestine and raised blood calcium

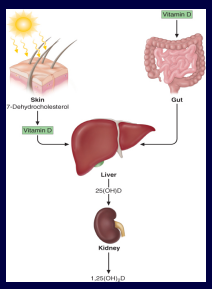

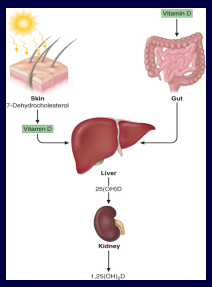

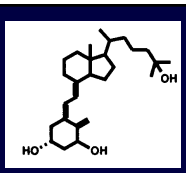

DNA binding

Hormone binding/gene activation

VDR

Vitamin D synthesis and activation

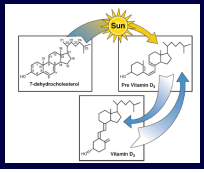

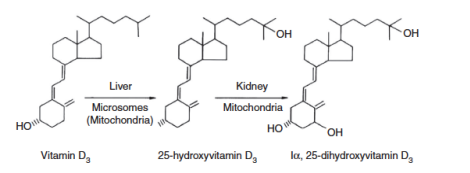

Renal 25-hydroxy vitamin D 1α-hydroxylation

- Renal secretion of active vitamin D ($1,25(OH)_2D_3$) is highly regulated
- Increased by PTH and low phosphorus
- Decreased by high levels of calcium or by FGF23
- Hormone or vitamin: vitamin in diet if not enough sun, then activated to form hormone in kidney

Calcium Homeostasis: vitamin D action

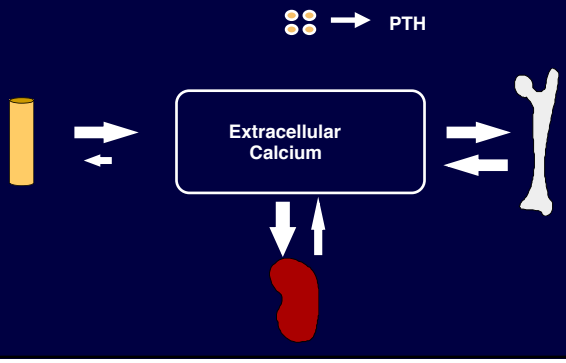

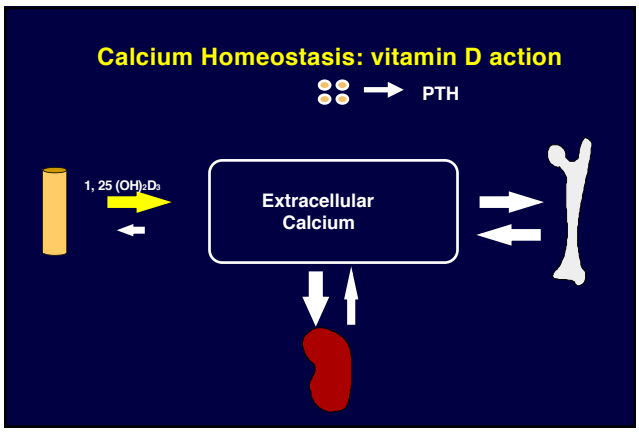
Calcium Homeostasis: vitamin D action
PTH
1, 25 (OH)2D3
Extracellular
Calcium

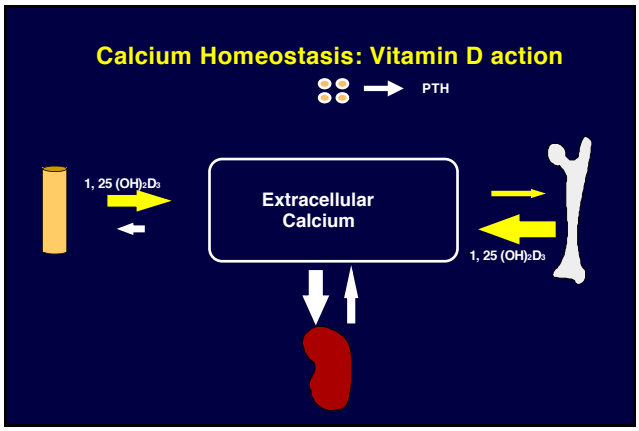
Calcium Homeostasis: Vitamin D action
PTH
1, 25 (OH)2D3
Extracellular
Calcium
1, 25 (OH)2D3

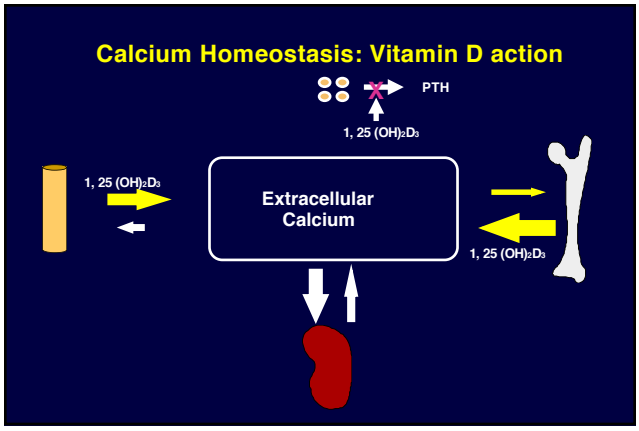
Calcium Homeostasis: Vitamin D action
PTH
1, 25 (OH)2D3
1, 25 (OH)2D3
Extracellular
Calcium
1, 25 (OH)2D3

Regulators of mineral metabolism

- Parathyroid hormone
- Vitamin D
- Fibroblast growth factor (FGF) 23
- Calcium
- Phosphate

FGF23

- Discovered in 2000 as gene mutated in autosomal dominant hypophosphatemic rickets
- Patients with rickets, low blood phosphate, and low or inappropriately normal levels of $1,25(OH)_2D_3$, inherited in an autosomal dominant fashion
- Gene discovered by positional cloning

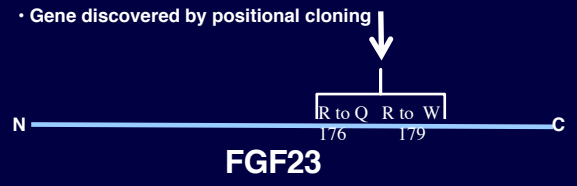

FGF23

- FGF23 acts on renal proximal tubule
  - causes phosphate loss in urine
  - suppresses 1-hydroxylation of 25-hydroxyvitamin D
- FGF23 is synthesized primarily by osteocytes
- FGF23 synthesis/secretion increased by $1,25(OH)_2D_3$ and phosphate

Phosphate Metabolism: roles of FGF23

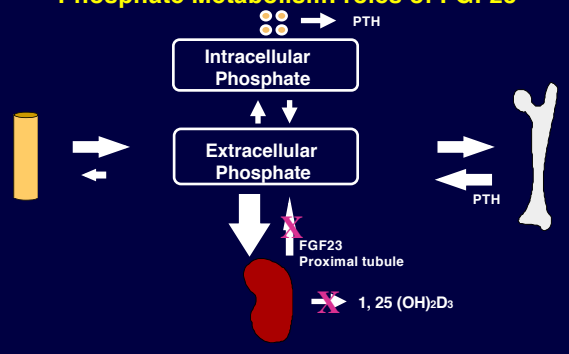

Regulators of mineral metabolism

- Parathyroid hormone
- Vitamin D
- Fibroblast growth factor (FGF) 23
- Calcium
- Phosphate